

Spontaneous Intracystic and Subdural Hemorrhage of an Arachnoid Cyst: A Case Report with Baseline Imaging of an Intact Cyst

Muhsin Özgün Öztürk¹, Zeynep Betül Deve¹

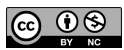Department of Radiology, Erzincan University, School of Medicine, Erzincan, Turkey

Cite this article as: Öztürk MÖ, Deve ZB. Spontaneous intracystic and subdural hemorrhage of an arachnoid cyst: A case report with baseline imaging of an intact cyst. *Current Research in MRI* 2023;2(3):70-71.

Corresponding author: Muhsin Özgün Öztürk, e-mail: ozturk_bul@hotmail.com

Received: October 12, 2023 **Accepted:** October 23, 2023 **Publication Date:** November 17, 2023

DOI:10.5152/CurrResMRI.2023.23081



Content of this journal is licensed under a Creative Commons Attribution-NonCommercial 4.0 International License.

Dear Editor,

I hope this letter finds you well. I am writing to present to you a recent medical event that we have encountered and found significant. This case involves a rare intracranial hemorrhage associated with an arachnoid cyst (AC).

Arachnoid cysts are benign fluid accumulations that develop between the inner and outer layers of the arachnoid in the cerebrospinal axis.¹ They usually form during childhood and are often detected incidentally.² However, approximately 5% of cases can lead to symptoms, including headaches, dizziness, vomiting, cognitive impairment, and, rarely, sensory-motor symptoms.³ On rare occasions, these cysts can become complicated, resulting in intracystic and/or subdural hemorrhages.¹⁻⁵

In this letter, we present the case of a 70-year-old male patient who experienced a rare event. The patient's history revealed the presence of a Galassi type 3 AC, measuring $7 \times 5 \times 5$ cm, in the left middle cranial fossa on computerized tomography (CT) and magnetic resonance imaging conducted within the past year (Figure 1, 2). This cyst triggered a spontaneous intracystic subacute hemorrhage, which subsequently led to an associated subacute subdural hematoma and the patient's current symptoms. The patient had no history of trauma at the time of presentation. Following a cranial CT scan, a 39-mm-thick subacute subdural hematoma was detected in the left frontotemporoparietal extra-axial

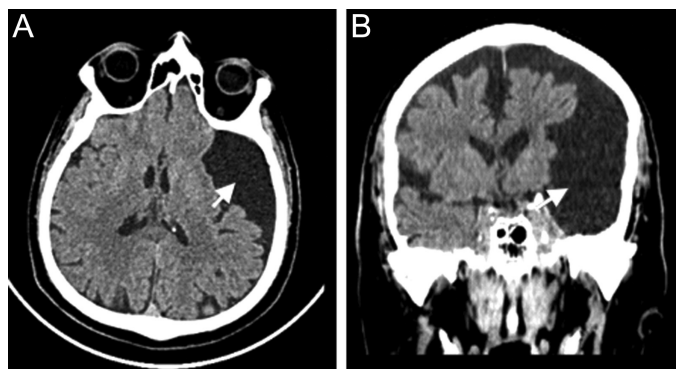


Figure 1. Computed tomography images of the patient a year ago: (A) Axial computed tomography: left-sided incidental $7 \times 5 \times 5$ cm Galassi type 3 arachnoid cyst (white arrow). (B) Coronal computed tomography: incidental left-sided $7 \times 5 \times 5$ cm Galassi type 3 arachnoid cyst (white arrow) displaces temporal lobes significantly and parietal and frontal lobes mildly.

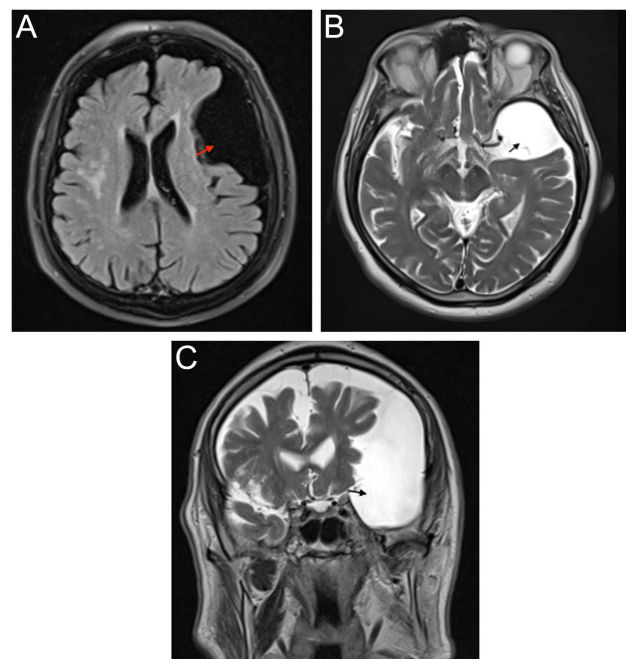


Figure 2. Magnetic resonance images of the patient a year ago: (A) Axial Fluid attenuated inversion recovery (FLAIR): left-sided intracranial Galassi type 3 arachnoid cyst (red arrow). (B) Axial T2-weighted magnetic resonance imaging: left-sided intracranial Galassi type 3 arachnoid cyst (black arrow). (C) T2-weighted coronal magnetic resonance imaging: left-sided intracranial Galassi type 3 arachnoid cyst (black arrow), which displaces temporal lobes significantly and parietal and frontal lobes mildly.

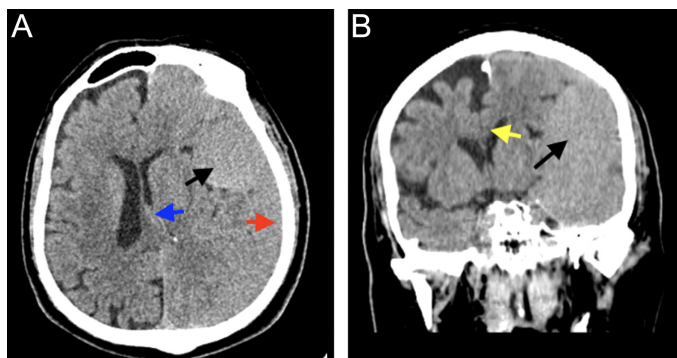


Figure 3. Computed tomography images at the time of admission: (A) Axial computed tomography: subacute subdural hemorrhage (red arrow) and accompanying intracystic subacute hemorrhage (black arrow), right-sided shift of midline structures (blue arrow) (B) Coronal computed tomography: subfalcine herniation to the right (yellow arrow) and accompanying intracystic subacute hemorrhage (black arrow).

space (Figure 3). Furthermore, the intracystic fluid within the AC appeared isodense compared to gray matter.

Considering the rapid progression of the patient's symptoms and the displacement of brain structures, a burrhole craniostomy was performed on the same day. A follow-up CT scan conducted 2 days later did not reveal any acute/subacute bleeding, but moderate subdural effusion was observed (Figure 4).

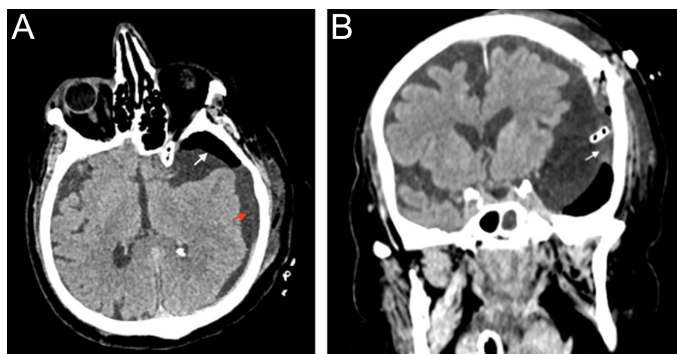


Figure 4. Postoperative computed tomography images after burrhole craniostomy: (A) Axial computed tomography: moderate subdural hypodense collection (red arrow) and post-operative extra-axial pneumocephalus (white arrow). (B) Coronal computed tomography: The border of arachnoid cyst adjacent to the subdural collection (white arrow).

According to recent reports, only 57 cases of spontaneous rupture and 32 cases of spontaneous intracystic hemorrhage have been documented in the literature, and around half of the patients with spontaneous intracystic hemorrhage were in childhood.^{2,3} Spontaneous subacute or acute intracystic hemorrhage with an imaging study prior to the hemorrhagic event is exceptionally rare, with only a few cases.¹

This case highlights a rare complication of ACs and underscores the importance of prompt medical intervention. Given the potential for spontaneous rupture of blood vessels within and around the cyst, patients with such cysts must be evaluated and treated promptly.³ In this case, having access to the patient's previous imaging allowed for a rapid diagnosis and, consequently, prompt treatment.

In conclusion, this rare case presentation aims to raise awareness regarding spontaneous intracystic and subdural hemorrhages associated with ACs and to encourage further research in the diagnosis and treatment of such cases.

Informed Consent: Written informed consent was obtained from patient who participated in this study.

Peer-review: Externally peer-reviewed.

Author Contributions: Concept – M.Ö.Ö.; Design – M.Ö.Ö., Z.B.D.; Supervision – M.Ö.Ö.; Resources – M.Ö.Ö.; Materials – M.Ö.Ö., Z.B.D.; Data Collection and/or Processing – M.Ö.Ö.; Analysis and/or Interpretation – M.Ö.Ö.; Literature Search – M.Ö.Ö., Z.B.D.; Writing Manuscript – M.Ö.Ö., Z.B.D.; Critical Review – M.Ö.Ö.

Declaration of Interests: The authors declare that they have no competing interest.

Funding: The authors declared that this study has received no financial support.

REFERENCES

1. Kim D, Yoo D. Intracystic hemorrhage of an arachnoid cyst: a case with prediagnostic imaging of an intact cyst. *Investig Magn Reson Imaging*. 2021;25(1):43-46. [\[CrossRef\]](#)
2. Ferreira TSH, Malveira LRC, Neto AG. Spontaneous subdural and intracavitary hemorrhage of temporal arachnoid cyst in an adult patient. *Interdisciplinary Neurosurgery*. 2021;23:100830. [\[CrossRef\]](#)
3. Leavitt LA, Nanda P, Stemmer-Rachamimov A, Dunn GP, Jones PS. Spontaneous rupture of an arachnoid cyst in an adult: illustrative case. *J Neurosurg Case Lessons*. 2023;5(7):CASE22420. [\[CrossRef\]](#)
4. Joel P, Anand K, Rami O A. Spontaneous intracystic hemorrhage in an adult with cerebellopontine angle arachnoid cyst and management: A case report. *Neurosurg Cases Rev*. 2021;4(2):070. [\[CrossRef\]](#)
5. Liu B, Wang C, Qu Y. Treatment of arachnoid cyst with spontaneous hemorrhage with atorvastatin. *Front Pharmacol*. 2019;10:1343. [\[CrossRef\]](#)