

Intradural Venous Sinus Cyst Mimicking Sinus Vein Thrombosis on Magnetic Resonance Venography

Önder Durmaz¹ , Kemal Buğra Memiş¹ , Erdal Karavaş² , Barış İrgül¹ 

¹Department of Radiology, Erzincan Binali Yıldırım University, Faculty of Medicine, Erzincan, Türkiye

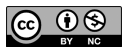
²Department of Radiology, Bandırma Training and Research Hospital, Balıkesir, Türkiye

Cite this article as: Durmaz Ö, Memiş KB, Karavaş E, İrgül B. Intradural venous sinus cyst mimicking sinus vein thrombosis on magnetic resonance venography. *Current Research in MRI*, 2024;3(2):57-59.

Corresponding author: Önder Durmaz, e-mail: dronzonder2577@gmail.com

Received: July 19, 2023 **Accepted:** September 5, 2023 **Publication Date:** October 6, 2023

DOI:10.5152/CurrResMRI.2023.23074



Content of this journal is licensed under a Creative Commons Attribution-NonCommercial 4.0 International License.

Abstract

Cerebral venous thrombosis is the obstruction of cranial venous pathways, including thrombosis in the cortical, dural, and deep cerebral veins. It constitutes 0.5%-1% of all strokes and is usually seen in young people. It is slightly more common in young women due to pregnancy, puerperium, and oral contraceptive use. Patients usually present with headaches or focal neurological deficits. Intradural venous sinus cysts are congenital and very rare pathologies. They are usually asymptomatic and detected incidentally. However, large cysts may be symptomatic when they disrupt the venous flow. Common symptoms are headaches and syncope. In this case, we present our 41-year-old female patient with complaints of headache, syncope, dizziness, ringing in the ears, and sleep disturbances that have been going on for 1 month. The patient's complete blood count revealed a normal hematocrit, hemoglobin, and red blood cell count. After clinical and laboratory exclusion of other differential diagnoses in the case, a magnetic resonance imaging (MRI) venography examination was requested with the preliminary diagnosis of dural sinus vein thrombosis. In the magnetic resonance venography examination performed in our case, an unenhanced 7 mm-diameter area was observed in the contrast-enhanced series. The diagnosis was primarily considered as cerebral venous sinus thrombosis. Our patient's complaints of severe headache, dizziness, and syncope were also consistent with our initial diagnosis. However, our patient did not benefit from the anticoagulant treatment given. For this reason, we turned to alternative diagnoses and performed a contrast-enhanced MRI. Our diagnosis changed to intradural venous sinus cyst after contrast-enhanced MRI examination.

Keywords: Arachnoid, cysts, dural sinuses, MRI

INTRODUCTION

Intradural venous sinus cysts are congenital and very rare pathologies.¹ They are usually asymptomatic and detected incidentally. However, large cysts may be symptomatic when they disrupt the venous flow. Common symptoms are headache and syncope.² Similar to other cystic lesions in the body, these lesions measure 0-30 Hounsfield Unit (HU) on brain computed tomography (CT) and appear isodense with cerebrospinal fluid. They are observed as intraluminal filling defects on contrast-enhanced examinations. Intradural venous sinus cysts appear isointense with cerebrospinal fluid in all sequences on MRI, that is, hypointense on T1-weighted and Fluid Attenuated Inversion Recovery (FLAIR) images and hyperintense on T2-weighted images.² Differential diagnoses include adipose tissue, arachnoid granulations, arachnoid cysts, and cerebral venous sinus thrombosis.^{3,4} Fat tissue is easily distinguished on CT and magnetic resonance (MR) images. Arachnoid granulations can be visualized inside the sinuses. These lesions appear as polypoidal structures in the sinus walls. Although arachnoid granulations can be mistaken for cysts in appearance, a close examination reveals CT intensities of less than 50 HU that appear as signal gaps on all MR sequences.³

CASE PRESENTATION

A 41-year-old female patient complained of severe headache, dizziness, and ringing in the ears for 1 month. The patient's complete blood count revealed a normal hematocrit, hemoglobin, and RBC count. After clinical and laboratory exclusion of other differential diagnoses in the case, an MRI venography examination was requested with the preliminary diagnosis of dural sinus vein thrombosis. On MR venography, a lesion thought to be a thrombus was seen in the left transverse sinuses (Figure 1). Thereupon, the patient was hospitalized, and anticoagulant was started. Our patient used anticoagulants; however, she applied to us again with the same complaints. In the tests performed, no problems were found in terms of anticoagulants and thrombophilia. The patient underwent a contrast-enhanced MRI the next day. And an unenhanced 7 mm-diameter area was observed in the contrast-enhanced series in the left transverse sinus (Figure 2). It was later found out that it was a cyst located in the left transverse sinus. Written informed consent was obtained from patient who participated in this study.

DISCUSSION

Intradural venous sinus cysts are congenital and very rare pathologies.¹ They are usually asymptomatic and detected incidentally. However, large cysts may be symptomatic when they disrupt the venous flow. Common symptoms are headache and syncope.² Similar to other cystic lesions

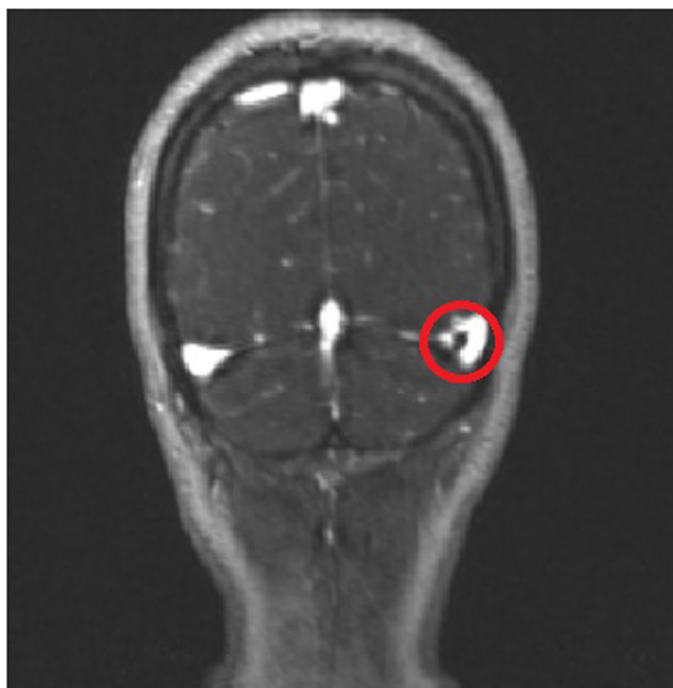

Figure 1. In the magnetic resonance venography image, a hypointense lesion (red circle) is seen in the left transverse sinus.

in the body, these lesions measure 0-30 HU on brain CT and appear isodense with cerebrospinal fluid. They are observed as intraluminal filling defects on contrast-enhanced examinations. Intradural venous sinus cysts appear isointense with cerebrospinal fluid in all sequences on MRI, that is, hypointense on T1-weighted and FLAIR images, and hyperintense on T2-weighted images (Table 1).²

Differential diagnoses include adipose tissue, arachnoid granulations, arachnoid cysts, and cerebral venous sinus thrombosis.^{3,4} Fat tissue is easily distinguished on CT and MR images. Arachnoid granulations can be visualized inside the sinuses. These lesions appear as polypoidal structures in the sinus walls. Although arachnoid cysts can be mistaken for cysts in appearance, a close examination reveals CT intensities of less than 50 HU that appear as signal gaps on all MR sequences (Table 2).³

Cerebral venous sinus thrombosis is diagnosed primarily by suspecting the clinical situation and showing thrombosis radiologically. Cerebral venous sinus thrombosis is seen in the superior sagittal and transverse

Table 1. Summary Table of Intradural Venous Sinus Cysts

Etiology	Clearly unknown
Incidence	Very rare
Gender ratio	Not known
Age predilection	Not known
Risk factors	Not known
Treatment	They may yet require conservative or surgical management in symptomatic patients.
Prognosis	
Findings on imaging	0-30 HU is measured on cranial computed tomography and is isodense with cerebrospinal fluid. Intradural venous sinus cysts appear isointense with cerebrospinal fluid in all sequences on MRI.

MRI, magnetic resonance imaging.

sinus thrombosis most frequently. Severe headache, which is the most important complaint of increased intracranial pressure, is seen in 90% of cases.⁵

Although CT and MR venography are the preferred techniques for imaging cerebral venous sinus thrombosis, currently the most basic diagnostic methods are cranial MRI and MR venography. In the MR venography examination performed in our case, an unenhanced 7 mm-diameter area was observed in the contrast-enhanced series. The diagnosis was primarily considered to be cerebral venous sinus thrombosis. Our patient's complaints of severe headache, dizziness, and syncope were also consistent with our initial diagnosis. However, our patient did not benefit from the anticoagulant treatment given. For this reason, we turned to alternative diagnoses and performed a contrast-enhanced MRI. Our diagnosis changed to intradural venous sinus cyst after contrast-enhanced MRI examination.

Similar symptoms in intradural venous sinus cysts and cerebral venous sinus thrombosis were the main factors that misled us. Even though, MR venography is the best method for the diagnosis of cerebral venous sinus thrombosis, this technique can fail to differentiate thrombosis from dural venous sinus cysts. In these kinds of situations, a contrast-enhanced MRI scan can aid to confirm diagnosis.

In conclusion, dural venous sinus cysts are very rare and can be confused with thrombosis by revealing similar symptoms. Contrast-enhanced MRI scans can be the key for differential diagnosis.

Teaching Point

Intradural venous sinus cysts are congenital and very rare pathologies. They are usually asymptomatic and detected incidentally. However,

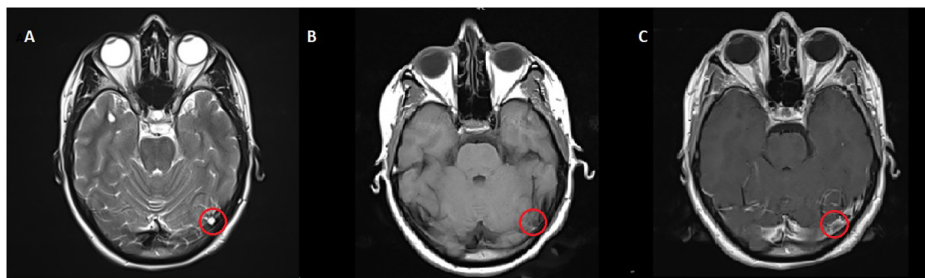

Figure 2. In the axial T2WI (A), a hyperintense lesion is seen in the left transverse sinus. The lesion shows no enhancement on pre- (B) and post-contrast (C) T1WIs. T1WI, T1-weighted image; T2WI, T2-weighted image.

Table 2. Differential Diagnosis Table for Intradural Venous Sinus Cysts

	CT	MRI
Intradural venous sinus cysts	0-30 HU is measured on cranial CT and is isodense with CSF.	Intradural venous sinus cysts appear isointense with CSF in all sequences on MRI.
Adipose tissue	Higher HU values—fat density	Signal loss in fat-saturated sequences, hyperintense on both T1WI and T2WI
Arachnoid granulations	These lesions appear as polypoidal structures in the sinus walls.	Signal characteristics are generally those of CSF.
Aeroceles	They appear as CT intensities of less than 50 HU.	They appear as signal gaps in all MR sequences.
Cerebral venous sinus thrombosis	Filling defect is visible in the sinus with contrast CT.	It is isointense on T1 sequences and hypointense on T2 sequences throughout the acute phase. It becomes hyperintense on T1 sequences during the subacute phase.

CSF, cerebrospinal fluid; CT, computed tomography; MRI, magnetic resonance imaging; T1WI, T1-weighted image; T2WI, T2-weighted image.

large cysts may be symptomatic when they disrupt the venous flow. Common symptoms are headaches and syncope. Contrast-enhanced MRI scans can be the key for differential diagnosis.

Informed Consent: Written informed consent was obtained from patient who agreed to take part in the study.

Peer-review: Externally peer-reviewed.

Author Contributions: Concept – Ö.D.; Design – Ö.D., K.B.M.; Supervision – E.K.; Resources – Ö.D., K.B.M.; Materials – Ö.D.; Data Collection and/or Processing – B.İ.; Analysis and/or Interpretation – E.K.; Literature Search – Ö.D., B.İ.; Writing Manuscript – Ö.D., E.K.; Critical Review – E.K., Ö.D.; Other – Ö.D.

Declaration of Interests: The authors have no conflict of interest to declare.

Funding: The authors declared that this study has received no financial support.

REFERENCES

1. Inagaki T, Yamanouchi Y, Nishimura T, Kawamura Y, Kawamoto K. Intracranial dural cyst. *Childs Nerv Syst.* 1998;14(1-2):69-73. [\[CrossRef\]](#)
2. Ojemann JG, Moran CJ, Gokden M, Dacey RG Jr. Sagittalsinusocclusion by intraluminal dural cysts. Report of two cases. *J Neurosurg.* 1999;91(5):867-870. [\[CrossRef\]](#)
3. Rastogi R. Intraluminal dural venous sinus cysts simulating as arocele in computerized tomography brain. *Ann Indian Acad Neurol.* 2008;11(2):116-118. [\[CrossRef\]](#)
4. Balo J. The dural venous sinuses. *Anat Rec.* 1950;106(3):319-324. [\[CrossRef\]](#)
5. Rodallec MH, Krainik A, Feydy A, et al. Cerebral venous thrombosis: multidetector CT angiography: tips and tricks. *RadioGraphics.* 2006;26(suppl 1):S5-18; discussion S42. [\[CrossRef\]](#)