

Morphological Analysis of Temporomandibular Joint According to Gender and Age Groups

Merve Kolak¹, Volkan Kızılgöz²

¹Erzincan Binali Yıldırım University, Oral and Dental Health Training and Research Hospital, Erzincan, Türkiye

²Department of Radiology, Erzincan Binali Yıldırım University Faculty of Medicine, Erzincan, Türkiye

Cite this article as: Kolak M, Kızılgöz V. Morphological analysis of temporomandibular joint according to gender and age groups. *Current Research in MRI*, 2024;3(2):39-42.

Corresponding author: Merve Kolak, e-mail: mervekolak@hotmail.com

Received: June 4, 2024 **Revision Requested:** June 15, 2024 **Last Revision Received:** July 8, 2024 **Accepted:** July 11, 2024

Publication Date: August 14, 2024

DOI:10.5152/CurrResMRI.2024.24100



Content of this journal is licensed under a Creative Commons Attribution-NonCommercial 4.0 International License.

Abstract

Objective: The purpose of this study was to assess the morphological parameters of the temporomandibular joint (TMJ) using magnetic resonance imaging in patients without TMJ pathologies. The findings of this investigation are expected to serve as reference values for clinical diagnosis and scientific research on temporomandibular disorders.

Methods: Magnetic resonance imaging images of 41 adult patients were examined. The condyle and glenoid fossa measurements were made in the sagittal plane. They were grouped by age, gender, and side, and statistical analysis was performed using the quantific anatomical values measured on magnetic resonance (MR) images.

Results: No statistical difference was observed between gender groups regarding all parameters. There was a significant, negative, low-level correlation between age and anterior condylar angle (ACoA) measurements on the left side. Considering the side comparisons, higher Glenoid Fossa Width (GFW) values ($P=.030$) were measured on the left side than on the right side. A significant, negative, low-level correlation between age and ACoA measurements was observed.

Conclusion: The correlation between age and ACoA measurements and GFW difference between different sides of the TMJ were the positive findings to be mentioned for his investigation. The morphological analyses focused on this anatomical region still need to be confirmed by the measurements performed on larger populations, since there are not many articles reporting specific results on this subject.

Keywords: Temporomandibular joint, anatomy, radiology, magnetic resonance imaging

INTRODUCTION

The temporomandibular joint (TMJ) is located between the fossa mandibularis and tuberculum articulare in the temporal bone and the caput mandibularis of the mandible. It is the only movable joint among the bones that make up the skull skeleton. There is an oval-shaped discus articularis between the joint surfaces. The discus articularis surrounds the joint surfaces all around and is adhered to the joint capsule. Temporomandibular joint is a synovial joint classified as a ginglymoarthrodial joint due to its surface shape and biaxial movements, rotational movement within the glenoid fossa, and translational movement along the articular process when opening the mouth.¹ Temporomandibular joint is one of the rarely encountered joints in the human body covered with fibrocartilage instead of hyaline cartilage.² It is thought that there is a certain correlation between the morphology of the TMJ and the functional loading from chewing forces.³ The size and shape of the articular disc and condyle were found to be substantially correlated with the onset of TMD in earlier research. In particular, the articular disc's size and morphology tightly correlate with the disc's anterior displacement, and the condyle's size and morphology strongly correlate with the development of osteoarthritis.⁴ There may be changes in TMJ morphology with aging, and differences between genders may occur.

Various imaging methods have been used to evaluate the morphology of the TMJ, such as panoramic radiography, computed tomography (CT), magnetic resonance imaging (MRI), cone beam computed tomography (CBCT), and ultrasound.⁵⁻⁷ Magnetic resonance imaging is the most preferred imaging modality due to its high resolution of soft tissue and cartilage. Additionally, by using magnetic resonance, it has the advantage of being a non-ionizing radiation imaging procedure compared to CT.⁸

Temporomandibular disorders (TMDs) are the most common diseases in the mouth, teeth, and jaw area.⁹ The aim of this study is to provide information to the literature by investigating the morphological properties of TMJ components with regard to age and gender groups using MR images.

MATERIAL AND METHODS

Patients

Our Institutional Ethics Committee approved this retrospective cross-sectional study. Since it was a retrospective study, informed consent was not required. This study has been approved by the Institutional Ethics Committee of Clinical Researches Erzincan Binali Yıldırım University non-invasive clinical research ethics committee (Number: 348349 2024-04/02, Session: 03, Date: 21.03.2024).

After ethics committee approval, all patients in a certain period of time (August 1, 2020 to December 31, 2023) over the age of 18 who underwent MRI examination for TMJ were included in the study. In the image archives, patients with bone damage such as osteoarthritis, traumatic arthritis, and infectious arthritis, and patients whose MR images cannot be reached in the medical records and image archives were excluded. Patients whose MR images were not suitable for evaluation due to artifacts or technical deficiencies ($n=2$), and patients under the age of 18 ($n=2$) were not included in the study. Patients with non-contrast MRI examinations with indications such as muscle diseases, intra-articular deformities, disc dislocations, intra-articular inflammatory diseases, and mandibular hypomobilities were studied. Following exclusions, 41 patients were re-interpreted regarding the morphological properties of the TMJ.

Magnetic Resonance Imaging

All temporomandibular MR images were obtained using T2-weighted coronal, T2-weighted sagittal, and T1-weighted sagittal planes. Sagittal plane T1-weighted closed-mouth images were used for morphological assessments. The imaging parameters were as follows: field of view (FOV): 140 mm, time of repetition (TR): 643 ms, time of echo (TE): 17, slice thickness: 2.5 mm, voxel size: $0.5 \times 0.5 \times 2.5$ mm for T1-weighted MR images.

Measurement Technique

We assessed the anterior–posterior length of condyles (AP LENGTHCo) in the sagittal plane MR images. AP LENGTHCo was measured as the interval between the most anterior and the posterior-most point of the condyle. The anterior condylar angle (ACoA) was assessed in the sagittal view as well and measured as the angle between the neck and head of the condyle using the anterior edges of these structures. Sagittal planes were also used for the articular fossa measurements. Glenoid Fossa Width (GFW) was determined as the distance between the post-glenoid process and the vertex of the joint eminence. The distance between the highest point of the fossa and the line between the post-glenoid process and the articular eminence vertex was considered for the assessment of the Glenoid Fossa Depth (GFD) in the study (Figure 1).

MAIN POINTS

- Previous studies revealed that the size and morphology of the mandibular condyle strongly related to temporomandibular dislocation onset.
- No significant statistical difference was found between male and female groups regarding the APLENGHTCo, GFW, GFD, ACoA measurements.
- A significant, negative, low level correlation between age and ACoA measurements was revealed on the left temporomandibular joint.
- Higher GFW values were measured for the left temporomandibular joint compared to the right side.

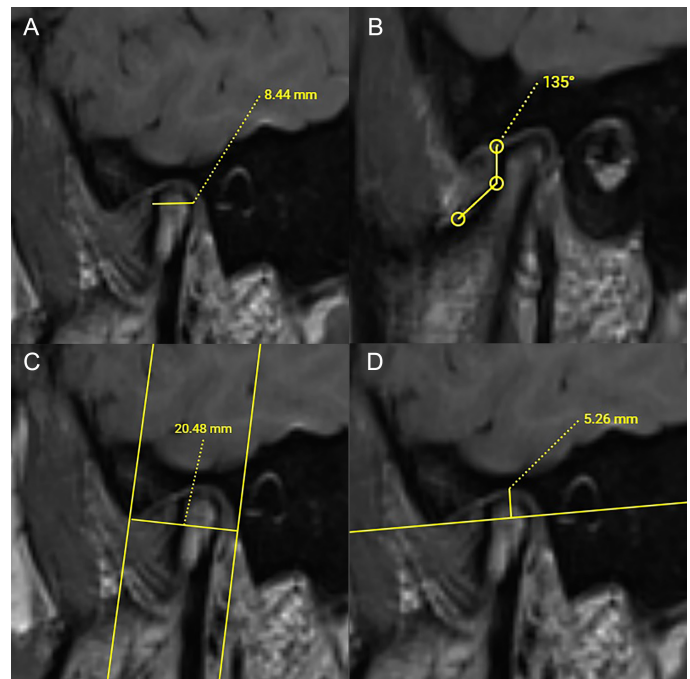


Figure 1. Measurement technique of the morphological parameters. The interval between the most anterior and posterior edges of the mandibular condyle as APLENGTHCo (A). ACoA was measured from the anterior edge, as the angle formed between the head and the neck of the mandibular condyle (B). GFW was determined as the distance between the post-glenoid process and the vertex of the joint eminence (C). The interval between the highest point of the fossa and the line between the post-glenoid process and the articular eminence vertex was considered as GFD (D). All measurements were performed on the sagittal MR images.

Statistical Analysis

Statistical analyses were performed using SPSS version 22.0 software program for Windows (IBM SPSS Corp.; Armonk, NY, USA). The percentage, frequency, mean, standard deviation, median, minimum, and maximum values were taken into account to be used or presented for descriptive statistics.

Glenoid fossa width, GFD, and APLENGHTCo values showed normal distribution in the Shapiro–Wilk Test. Therefore, parametric test procedures were used for comparisons regarding age and gender differences. In this context, the independent samples *t*-test was used to determine the relationship between the parameters. In order to perform the statistics regarding the ACoA, non-parametric tests were applied to indicate these relationships due to the data distribution characteristics. Thus, Mann–Whitney *U* and Spearman’s rho correlation tests were carried out for this parameter and related statistical calculations.

The results were evaluated within the 95% CI, and a $P < .05$ was considered to indicate statistical significance.

RESULTS

There were 41 MRI images re-interpreted to reveal the morphological properties of the TMJ in this research (the mean age was 39.45 ± 14.02). Thirty-one (75.6%) of them were females, and 10 (24.4%) were males in the study group (Table 1).

No significant statistical difference was found between male and female groups regarding the APLENGHTCo, GFW, GFD, and ACoA

Table 1. The Measurement Results of the Morphological Parameters Regarding Sexes

Parameter	Female				Male				Total			
	Min	Max	Mean	SD	Min	Max	Mean	SD	Min	Max	Mean	SD
APLengthCo	2,73	10,27	6,03	1,60	3,50	7,83	5,35	1,33	2,73	10,27	5,86	1,56
ACoA	107,50	159,63	142,36	10,25	113,55	156,04	141,04	11,00	107,50	159,63	142,04	10,38
GFW	10,54	19,89	15,38	1,90	11,28	18,41	14,90	1,57	10,54	19,89	15,26	1,82
GFD	1,36	6,83	3,71	1,03	1,28	6,09	3,68	1,10	1,28	6,83	3,71	1,04

Min, Minimum value; Max, Maximum value; SD, Standart deviation; APLengthCo, Anteroposterior condyle length; ACoA, Anterior condyle angle; GFW, Glenoid fossa width; GFD, Glenoid fossa depth.

measurements. Age was another aspect studied in this research, and a significant, negative, low-level correlation between age and ACoA measurements on the left side.

In the comparison of the right and left sides for all of the measured parameters of the patients, a statistically significant difference for GFW value ($P=.030$) was observed, with higher GFW values measured on the left side compared to the right side for this parameter. APLENGHTCo, GFD, and ACoA values indicated no difference between the measurements on the left and the right sides.

DISCUSSION

This study focused on the versatility of the morphological features of the temporomandibular joint according to gender and age. According to the research results, no statistically significant differences were found when APLENGTHCo and GFD parameters were evaluated in terms of age, gender, and side. A significant, negative, low-level correlation was found between age and the left ACoA. When evaluated by side, it was seen that the GFW value of the left side was higher than on the right side.

The TMJ is one of the most significant and unique joints in the human body regarding its biomechanical features, but especially considering the cartilaginous content of this articulation. Understanding the anatomy of the TMJ is essential for distinguishing anatomical variations and pathological conditions.¹⁰ Morphological variations of the components of the TMJ are significant in understanding the TMJ's normalcy, function, and potential pathological conditions, as well as offering suitable management and treatment.¹¹ Several studies have been undertaken to investigate the relationship between morphological and morphometric variations of the TMJ and their associations with pathological alterations based on gender and age.¹²⁻¹⁴ The inclination of the articular eminence can affect the range of condyle excursion movement.⁶ Patients with accentuated articular eminences had broader condyle-disc movement during function, which can increase the risk of elongating the posterior ligament and causing disc problems.¹⁵ The articular eminence shape and inclination have also been identified as predisposing variables for disc dislocations.¹⁵

Even though the cortical borders of the bone can be visualized clearly by CT, MR images were chosen to perform the measurements in this study. The tendency of clinicians and surgeons to choose MRI instead of CT, due to the ability for detailed soft tissue imaging and visualization of the articular cartilage along with other bony compartments, provided a larger patient pool and data to study with a higher number of patients to measure.

In numerous reports mentioning temporomandibular dislocation, the morphological properties were revealed to be significantly associated with structural changes within the TMJ. Research shows that there is a

relationship between condyle size and disc displacement. It is thought that the risk of developing TMD is higher in individuals with small condyle sizes.¹⁶

According to APLENGHTCo measurements, Coombs et al ($n=22$) and de Pontes ($n=186$) found that males had higher values than females in their study results, with both researchers using MR images to obtain data.^{17,18} Regarding the studies using CBCT, Yasa et al ($n=400$) and Al-koshab et al ($n=200$) found higher APLENGHTCo measurement results in males parallel to those MRI studies.^{19,20} In this current study, no significant statistical difference was found between males and females.

Derwich et al ($n=210$) performed GFD and GFW measurements using CBCT; however, the researchers did not evaluate the results in terms of gender. The average GFD was 9.8 mm and the average GFW was 20.5 mm according to their study results.²¹ In this current research, GFD and GFW were evaluated and analyzed regarding age, gender, and different sides. The final results of this study indicated that only the left GFW values were higher than the right side, and no other differences were observed regarding these parameters in terms of age and gender.

There are few studies in the literature on ACoA measurements and the data distribution of this parameter concerning age and gender.

In the literature, ACoA measurements were mentioned in Torres et al's study; however, the study compared the patients with and without temporomandibular disc dislocations and did not address gender comparisons in normal individuals.²² There was a significant, negative, low-level correlation on the left side between age and ACoA measurements in this current study presented to the literature.

Before analyzing the study results of this current research, readers should be aware of some limitations in planning, the study process, and considering the data pool of this investigation. First of all, the measurement data were examined based on a single reviewer's measurements, without considering intraobserver agreement. Having two or more reviewers would help compare results from different reviewers and identify interobserver differences. This would also be beneficial for the accuracy of the study results. The sample size of the study was relatively small, as the data were obtained from a single health center. A larger sample size, including different institutions or various geographical regions, would be better and may influence the study results. To maximize the study population, MR images were chosen as clinicians prefer this modality more than other imaging procedures to examine the joint and the articular disc simultaneously. However, CT images would be more effective to measure the bony morphology, which has been investigated in this research. The data obtained by radiological measurements on MR images could not be verified with a

gold standard, such as surgical outcomes, and may not reflect accurate results as measurements performed in cadaveric studies. This situation can be considered another limitation of this study.

There is limited literature on the morphological analyses of the temporomandibular joint and its relationships with age and gender. This investigation found a significant, negative, low-level correlation between age and ACoA measurements. Additionally, both temporomandibular joints of each individual were compared with each other regarding the morphological parameters, and higher GFW values were measured on the left side compared to the right side for this anatomical approach.

Ethics Committee Approval: This study has been approved by the institutional ethics committee Ethics Committee of Clinical Researches Erzincan Binali Yıldırım University non-invasive clinical research ethics committee (Number: 348349 2024-04/02, Session: 03, Date: 21.03.2024).

Informed Consent: N/A.

Peer-review: Externally peer-reviewed.

Author Contributions: Concept – M.K., V.K.; Design – M.K., V.K.; Supervision – V.K.; Resources – M.K., V.K.; Materials – M.K., V.K.; Data Collection and/or Processing – M.K., V.K.; Analysis and/or Interpretation – M.K.; Literature Search – M.K., V.K.; Writing Manuscript – M.K.; Critical Review – V.K.

Declaration of Interests: The authors have no conflict of interest to declare.

Funding: The authors declared that this study has received no financial support.

REFERENCES

1. Bag AK, Gaddikeri S, Singhal A, et al. Imaging of the temporomandibular joint: an up-date. *World J Radiol.* 2014;6(8):567-582. [\[CrossRef\]](#)
2. Vos LM, Kuijjer R, Huddleston Slater JJR, Bulstra SK, Stegenga B. Inflammation is more distinct in temporomandibular joint osteoarthritis compared to the knee joint. *J Oral Maxillofac Surg.* 2014;72(1):35-40. [\[CrossRef\]](#)
3. Jiang H, Li C, Wang Z, et al. Assessment of osseous morphology of temporomandibular joint in asymptomatic participants with chewing-side preference. *J Oral Rehabil.* 2015;42(2):105-112. [\[CrossRef\]](#)
4. Bagis B, Ayaz EA, Turgut S, Durkan R, Özcan M. Gender difference in prevalence of signs and symptoms of temporomandibular joint disorders: a retrospective study on 243 consecutive patients. *Int J Med Sci.* 2012;9(7):539-544. [\[CrossRef\]](#)
5. Ahmed NF, Samir SM, Ashmawy MS, Farid MM. Cone beam computed tomographic assessment of mandibular condyle in Kennedy class I patients. *Oral Radiol.* 2020;36(4):356-364. [\[CrossRef\]](#)
6. Rabelo KA, Sousa Melo SL, Torres MGG, Campos PSF, Bento PM, Melo DP de. Condyle excursion angle, articular eminence inclination, and temporomandibular joint morphologic relations with disc displacement. *J Oral Maxillofac Surg.* 2017;75(5):938.e1-938.e10. [\[CrossRef\]](#)
7. Talmaceanu D, Lenghel LM, Bolog N, et al. Imaging modalities for temporomandibular joint disorders: an update. *Chujul Med.* 2018;91(3):280-287. [\[CrossRef\]](#)
8. Tomura N, Otani T, Narita K, et al. Visualization of anterior disc displacement in temporomandibular disorders on contrast-enhanced magnetic resonance imaging: comparison with T2-weighted, proton density-weighted, and precontrast T1-weighted imaging. *Oral Surg Oral Med Oral Pathol Oral Radiol Endod.* 2007;103(2):260-266. [\[CrossRef\]](#)
9. Wilentz JB, Cowley AW. How can precision medicine be applied to temporomandibular disorders and its comorbidities? *Mol Pain.* 2017;13:1744806917710094. [\[CrossRef\]](#)
10. Praveen BN SH. Morphological and radiological variations of mandibular condyles in health and diseases: A systematic review. *Dentistry.* 2013;03(1). [\[CrossRef\]](#)
11. Zhang Y, Xu X, Liu Z. Comparison of morphologic parameters of temporomandibular joint for asymptomatic subjects using the two-dimensional and three-dimensional measuring methods. *J Healthc Eng.* 2017;2017:5680708. [\[CrossRef\]](#)
12. Kurita H, Ohtsuka A, Kobayashi H, Kurashina K. Relationship between increased horizontal condylar angle and resorption of the posterosuperior region of the lateral pole of the mandibular condyle in temporomandibular joint internal derangement. *Dento Maxillo Facial Rad.* 2003;32(1):26-29. [\[CrossRef\]](#)
13. Sa SC, Melo SLS, Melo DP, Freitas DQ, Campos PSF. Relationship between articular eminence inclination and alterations of the mandibular condyle: a CBCT study. *Braz Oral Res.* 2017;31:e25. [\[CrossRef\]](#)
14. Margarida I, Crusoé-Rebello R, Sérgio P, et al. Evaluation of the relation between the horizontal condylar angle and the internal derangement of the TMJ-a magnetic resonance imaging study Avaliação da relação entre o ângulo horizontal do côndilo e o desarranjo interno da ATM, por meio de ressonância magnética. *Pesqui Odontol Bras.* 2003;17(2):176-182.
15. Sharma S, Gupta DS, Pal US, Jurel SK. Etiological factors of temporomandibular joint disorders. *Natl J Maxillofac Surg.* 2011;2(2):116-119. [\[CrossRef\]](#)
16. Guercio Monaco E, De Stefano AA, Hernandez-Andara A, Galluccio G. Correlation between condylar size on CT and position of the articular disc on MRI of the temporomandibular joint. *Cranio.* 2022;40(1):64-71. [\[CrossRef\]](#)
17. de Pontes MLC, Melo SLS, Bento PM, Campos PSF, de Melo DP. Correlation between temporomandibular joint morphometric measurements and gender, disk position, and condylar position. *Oral Surg Oral Med Oral Pathol Oral Radiol.* 2019;128(5):538-542. [\[CrossRef\]](#)
18. Coombs MC, Bonthius DJ, Nie X, Lecholop MK, Steed MB, Yao H. Effect of measurement technique on TMJ mandibular condyle and articular disc morphometry: CBCT, MRI, and physical measurements. *J Oral Maxillofac Surg.* 2019;77(1):42-53. [\[CrossRef\]](#)
19. Al-Koshab M, Nambiar P, John J. Assessment of condyle and glenoid fossa morphology using CBCT in South-East Asians. *PLoS One.* 2015;10(3):e0121682. [\[CrossRef\]](#)
20. Yasa Y, Akgül HM. Comparative cone-beam computed tomography evaluation of the osseous morphology of the temporomandibular joint in temporomandibular dysfunction patients and asymptomatic individuals. *Oral Radiol.* 2018;34(1):31-39. [\[CrossRef\]](#)
21. Derwich M, Mitus-Kenig M, Pawlowska E. Temporomandibular joints' morphology and osteoarthritic changes in cone-beam computed tomography images in patients with and without reciprocal clicking-A case control study. *Int J Environ Res Public Health.* 2020;17(10). [\[CrossRef\]](#)
22. Torres MGG, Crusoé-Rebello IM, Rosário M, Albuquerque MC, Campos PSF. Morphometric features of the mandibular condyle and association with disk abnormalities. *Oral Surg Oral Med Oral Pathol Oral Radiol.* 2016;121(5):566-572. [\[CrossRef\]](#)